

# Initial apical fit of K-files versus LightSpeed LSX instruments assessed by micro-computed tomography

M. Marending, O. O. Schicht & F. Paqué

Division of Endontology, Department of Preventive Dentistry, Periodontology and Cariology, University of Zürich, Zürich, Switzerland

## Abstract

**Marending M, Schicht OO, Paqué F.** Initial apical fit of K-files versus LightSpeed LSX instruments assessed by micro-computed tomography. *International Endodontic Journal*.

**Aim** To compare the apical fit in two dimensions of the first K-file versus the first Lightspeed LSX instrument binding at working length after an initial crown-down preparation.

**Methodology** Twenty maxillary molars with fully developed roots and four separate root canals were selected. Canals were pre-flared with ProFile.04 taper instruments to three quarters of estimated working length. Working length was electronically determined using a size 06 K-file. Progressively larger K-files were inserted passively to working length. The first binding K-file was termed initial apical file (IAF). Then, the first binding LSX initial apical lightspeed-instrument (IAL) was determined. Teeth were scanned with and without instruments in place using micro-computed tomogra-

phy. Cross-sections of the apical part of the root canals were analysed as follows: the largest and smallest diameters of the root canal and the diameter of the instrument were calculated and related to each other. Statistics were performed using Kruskal–Wallis test and Wilcoxon test. The alpha-type error was set at 0.05.

**Results** Initial apical file sizes ranged from 8 to 30 and were lowest in second mesiobuccal and highest in palatal canals. IAL sizes ranged from size 20 to 40. The apical large canal diameter was assessed more accurately by the LSX instruments ( $P < 0.0001$ ). However, the smallest available LSX instrument (i.e. size 20) did not reach working length in 39 of 80 canals.

**Conclusions** Instruments with a flat widened tip were found to determine apical cross-sectional diameter better than round, tapered instruments.

**Keywords:** apical diameter, canal shape, LightSpeed LSX, micro-computed tomography.

Received 28 June 2011; accepted 8 September 2011

## Introduction

Effective root canal debridement requires adequate apical enlargement. Root canal walls should be disinfected without weakening the root by excessive dentine removal (Lang *et al.* 2006). Therefore, whilst cleaning and shaping, there are three critical parameters that the clinician must determine: the length of

the canal, the taper of the preparation and the horizontal dimension of the preparation at its most apical extent (Jou *et al.* 2004). The latter is determined by the cross-sectional diameter of the canal in mesiodistal and buccolingual directions (Jou *et al.* 2004). If the treatment goal is mechanical debridement of the canal wall, then the factor that determines minimal instrumenting size is the large diameter, which is almost always the buccolingual diameter of the canal (Wu *et al.* 2000).

Horizontal canal dimensions are usually sized using K-files. In the past, different research groups tried to estimate the apical root canal diameter using endodontic instruments. They demonstrated that

Correspondence: Dr Frank Paqué, Division of Endontology, Department of Preventive Dentistry, Periodontology and Cariology, University of Zürich Center for Dental Medicine, Plattenstrasse 11, 8032 Zürich, Switzerland (e-mail: frank.paque@zzm.uzh.ch).

pre-flaring of the coronal and middle thirds of root canals improved the determination of the apical root canal diameter (Wu *et al.* 2000, Pecora *et al.* 2005, Ibelli *et al.* 2007). In these studies, pre-flaring allowed an increase in instrument size binding at working length, which was reflected in lower discrepancy values between file and anatomical diameter. However, the instrument binding technique using conventional K-files or modified LightSpeed instruments did not reflect the apical diameter of root canals precisely at working length (Wu *et al.* 2002, Pecora *et al.* 2005, Weiger *et al.* 2006, Ibelli *et al.* 2007, Paqué *et al.* 2010).

Paqué *et al.* (2010) evaluated in two and three dimensions the fit of the first binding K-file at working length after a crown-down procedure in maxillary molars using microcomputed tomography ( $\mu$ CT). They concluded that although the operator's tactile sense to feel apical binding was correct in 95% of cases, the apical fit of the initial apical file was poor. The round shape of the K-file did not correspond to the apical canal anatomy of maxillary molars. Wu *et al.* (2000) investigated the apical root canal diameters in 180 extracted human teeth (20 teeth for each tooth group) by sectioning them horizontally at 1, 2, 3, 4 and 5 mm from the apex. They found a long-oval root canal shape (ratio of long/short canal diameters between 2 and 4) in the apical sections of maxillary molar teeth up to 30% in distobuccal, 24% in palatal, 33% in first and 80% in second mesiobuccal root canals. These findings would indicate that an instrument with an oval-shaped cross-section could be more accurate for the determination of the apical root canal diameter.

The only instruments available on the dental market with this kind of cross-section are the LightSpeed LSX instruments (Discus Dental, Culver City, CA, USA). These instruments have a long, nontapered, flexible shaft like the original LightSpeed instruments. However, their apical part is completely different. The blade is not machined but stamped or coined into an oval-shaped design (Iqbal *et al.* 2007). This instrument has the potential to bypass the canal curvature more readily than a more rigid stainless steel file, and the apical third of the root canal could be easily reached. Furthermore, the flattened cross-section of a LightSpeed LSX instrument should fit more accurately in the apical region and give more reliable measurements of wider canals than the round K-file. This hypothesis was tested in the current study on extracted human maxillary molars with four root canals.  $\mu$ CT scans were used to

assess the fit of the first instrument binding at working length.

## Materials and methods

### Selection of teeth

Twenty human maxillary molars with three roots, stored in 0.1% thymol after extraction, were selected after pre-scans using a high-resolution  $\mu$ CT system ( $\mu$ CT 40; Scanco Medical, Brüttisellen, Switzerland). The teeth were selected based on their morphological appearance (i.e. fully formed apices, four independent root canals and separate apical foramina).

### Preparation of teeth

The apical thirds of the roots were isolated with wax, whilst the rest of the outer root surfaces were sealed with two layers of nail varnish. To allow exact superimposition of the different 3D images, the teeth were mounted and embedded on SEM stubs (014001-T; Balzers Union AG, Balzers, Liechtenstein). After embedding, the wax was removed to allow electrical measurements of the root canal length.

All endodontic procedures were carried out by an experienced endodontist (M.M.) who was familiar with the preparation system. Endodontic access cavities were prepared using diamond burs (Dentsply Maillefer, Ballaigues, Switzerland), and the occlusal surfaces were flattened to ensure clearly defined reference points for maintaining working length. The canal orifices were explored using size 10 K-files and were then enlarged with Gates Glidden burs (nos 3–1; Dentsply Maillefer) resulting in a step-down preparation with a maximum insertion depth of 3 mm. The coronal and middle third of the root canals were then pre-flared with ProFile .04 taper instruments (sizes 45, 40, 35, 30, 25, 20; Dentsply Maillefer) in a crown-down sequence. Further probing the canals to check for patency was avoided so as not to modify the canal's apical anatomy. Crown-down preparation was performed until 3/4 of the estimated working length was reached. All files were used with light apical pressure at constant speed of 250 r/min in a hand-piece powered by a torque-controlled electric motor (ATR Technica; Dentsply Maillefer). Sodium hypochlorite (1% NaOCl) was used to irrigate and was delivered with a 30-gauge needle (Max-i-probe; Dentsply Maillefer). Two millilitres of irrigant per canal was used between each file size.

The individual working length was established electrometrically (Root ZX; Morita, Tokyo, Japan) in a physiological saline (0.9% NaCl) bath to simulate the clinical situation (Weiger *et al.* 1999). Size 06 K-files (Dentsply Maillefer) attached to the Root ZX fileclip were inserted until the display indicated 'apex', and then, 0.5 mm was subtracted from this length to determine the individual canal working length.

### Determination of binding instruments

The first binding K-file (Initial Apical File, IAF) and the first binding LSX instrument (Initial Apical Lightspeed-instrument, IAL) were determined for each individual canal. The instruments were gently introduced by hand to working length in ascending order beginning with size 8 for K-files and size 20 for LSX instruments. Using the LSX, partial rotation of the instruments was allowed to guide the oval instrument tip in the apical area. The position of the IAF and IAL was verified electrometrically.

### Micro-CT measurements

Specimens were scanned several times using a commercially available  $\mu$ CT system ( $\mu$ CT-40; Scanco Medical). A first scan of the mounted teeth was taken before performing any endodontic procedure at an isotropic resolution of 20  $\mu$ m at 70 kV and 114  $\mu$ A. A fixed threshold was applied to separate dentine from root canals, and binary images of the root canals were produced. Although the mounting on SEM carriers ensured almost exact repositioning of the specimens for both scanning procedures, superimposition was calculated subsequently with recently developed software (IPL Register 1.01beta; Scanco Medical). Before and after each treatment step, roots were registered with rigid 3D rotation and translation. This was determined by maximizing the cross-correlation of the overlaid 3D data sets of the outer contours of the tooth, which do not change during the treatment procedures. This was performed with an accuracy better than one voxel as determined on two test scans of an untreated tooth, where the subtraction image of the co-registered scans showed discrepancies <1 voxel (i.e. only a few isolated noise points remained). One additional scan was taken, after determining the IAF and IAL in each root canal, to analyse the apical part of the roots. The apical part of each tooth was scanned at 70 kV and 114  $\mu$ A with an isotropic resolution of 10  $\mu$ m resulting in 550–800 slices for the apical part of each tooth. The volume of

interest was determined to include the apical 2.5 mm of the K-file or the apical 2 mm of the LSX instrument and the apex of each root. Scans were taken with empty root canals and with fixed IAF or IAL in each root canal at working length. For scans with the IAF and IAL *in situ*, the integration time of the scanner device was set to maximum (i.e. factor 10 $\times$ ) to reduce the noise and the scattering effect caused by the radiopaque instruments.

### Data generation and analysis

For 2D evaluations of the apical root canals, with and without the instruments in place, the cross-sections of interest were calculated from the root tip, which served as a reference point for all scans. Subsequently, the scanned root apices were reconstructed and superimposed on each other. Thus, two sets of segmented root canals (with and without IAF *in situ*) were matched exactly and could be visualized three-dimensionally.

Scans from LSX instruments revealed that the location and the length of the largest diameter of the cutting head varied. For this reason, the 2D measurements with and without the IAL in place were taken in the area of the largest instrument cross-section, which was 200–550  $\mu$ m coronally from the instrument tip. Measurements with the IAF in place were taken 1 mm coronally from the instrument tip. Values of 2D measurements were grouped according to canal type (first mesiobuccal, second mesiobuccal, distobuccal and palatal).

Data for the ratio of long/short diameters in the apical part of the root canals and the ratio of instrument size to the long root canal diameter were skewed (Shapiro–Wilk test) and therefore compared using Kruskal–Wallis test and Wilcoxon test. The alpha-type error was set at 0.05.

### Results

The ratio of long/short diameters in the apical part of the first mesiobuccal, second mesiobuccal, distobuccal and palatal root canals (Table 1) indicated oval cross-sections in the palatal canals, oval-to-long-oval cross-sections in the first mesiobuccal canals, long-oval cross-sections in the distobuccal canals and flattened cross-sections in the second mesiobuccal canals. Differences in ratios between canal types were statistically significant ( $P < 0.01$ ; Table 1).

Initial apical file sizes ranged from size 8 to 30 and were lowest in second mesiobuccal and highest in palatal canals. IAL sizes ranged from 20 to 40. In 39 of

**Table 1** Ratio of long/short diameters in the apical part of root canals; all presented as median values and inter-quartile ranges

| Canal                         | First       | Second      | Distobuccal | Palatal   |
|-------------------------------|-------------|-------------|-------------|-----------|
|                               | mesiobuccal | mesiobuccal |             |           |
| Ratio of long/short diameters | 1.9 (0.8)   | 3.3 (5.6)   | 2.4 (1.9)   | 1.5 (0.6) |
| Wilcoxon test                 | A           | B           | A, B        | A         |

There was no statistically significant difference between the groups with same letter.

80 root canals, the determination of IAL was not possible, because the operator was not able to reach the working length passively with the smallest available size 20 LSX instruments (Table 2). The IAF sizes determined in these canals were eight (seven canals), 10 (18 canals) and 15 (14 canals). The median long and short apical diameter was greater in canals where LSX instruments reached the working length compared to canals where LSX instruments did not reach the working length (Table 4). Median short diameter was approximately twice as high in canals where LSX instruments reached the working length (Table 4). In 15 canals, the IAF sizes were 15 or smaller, and in 26 canals, the IAF sizes were 20 or larger. When it was possible to reach working length passively using an LSX instrument, its size was larger than that of the IAF in almost all canals (36 of 41 canals). In these canals, the IAL was one (in 23 canals), two (in 10 canals) or even three sizes (in three canals) larger than the IAF. This comparison showed that the apical large diameter of the root canal was assessed more accurate by the LSX instrument ( $P < 0.0001$ ; Table 3, Figs 1 and 2).

## Discussion

The current investigation compared the fit of the first LSX instrument and K-file binding at working length in 20 maxillary molars with four independent root canals. The large diameter of the root canal was better reflected

by the oval-shaped LSX instrument tip than by the round, tapered K-file. However, a precise estimation of the apical canal dimensions was not possible with either instrument type.

The apical portion of the root canal system can retain micro-organisms that may cause periradicular inflammation. Treatments that maximize removal of pathogens should be used. Larger instrumentation is beneficial in reducing the debris and number of remaining bacteria in the apical third of the canal (Wu & Wesselink 1995, Tan & Messer 2002, Usman *et al.* 2004). It appears to be necessary to accurately measure the size of any individual canal before apical enlargement. Otherwise, some canals will be insufficiently shaped, whilst others could be over-prepared. Root canal anatomy can be complex; average sizes and the cross-sectional shape vary considerably, not only between but also within canals (Hess 1917, Kerekes & Tronstad 1977a,b,c, Wu *et al.* 2000). Today, using  $\mu$ CT, forms and dimensions can be visualized and calculated in the *ex vivo* situation in a highly accurate manner. Estimations of root canal dimensions of the same tooth can be carried out repeatedly using different instruments. The results can be compared two- and three-dimensionally at different levels without destroying the tooth.

Measurements with the IAF were taken 1 mm coronally from the instrument tip, to be comparable with previous studies (Gani & Visvisian 1999, Wu *et al.* 2002, Weiger *et al.* 2006, Paqué *et al.* 2010). The measurements with the IAL in place were not taken 1 mm coronally from the instrument tip but in the region where the cutting head of the LSX instruments showed the largest diameter. This was found to be 200–550  $\mu$ m coronally from the instrument tip. Consequently, measurements with the two different instrument types were not taken exactly at the same level. However, the canal diameter did not differ greatly between these two levels.

Maxillary molars were used for this study because these teeth frequently have four canals with great variability in root canal shape, size and length. In a previous study (Paqué *et al.* 2010), estimation of the

**Table 2** Initial apical file (IAF) and initial apical LightSpeed LSX-instrument (IAL) in different root canals in which LSX instruments reached working length passively ( $n = 41$ )

| Canal              | <i>n</i> | IAF 10 | IAF 15 | IAF 20 | IAF 25 | IAF 30 | IAL 20 | IAL 25 | IAL 30 | IAL 35 | IAL 40 |
|--------------------|----------|--------|--------|--------|--------|--------|--------|--------|--------|--------|--------|
| First mesiobuccal  | 8        | 1      | 6      | 1      |        |        | 6      | 1      |        | 1      |        |
| Second mesiobuccal | 1        |        | 1      |        |        |        | 1      |        |        |        |        |
| Distobuccal        | 12       |        | 6      | 4      | 2      |        | 6      | 3      | 2      | 1      |        |
| Palatal            | 20       |        | 1      | 6      | 8      | 5      | 2      | 3      | 8      | 5      | 2      |
| Total              | 41       | 1      | 14     | 11     | 10     | 5      | 15     | 7      | 10     | 7      | 2      |

**Table 3** Ratio of instrument size (IAF and IAL) to long root canal diameter in per cent; all presented as median and inter-quartile ranges

|     |             |
|-----|-------------|
| IAF | 46.3 (24.7) |
| IAL | 78.1 (33.3) |

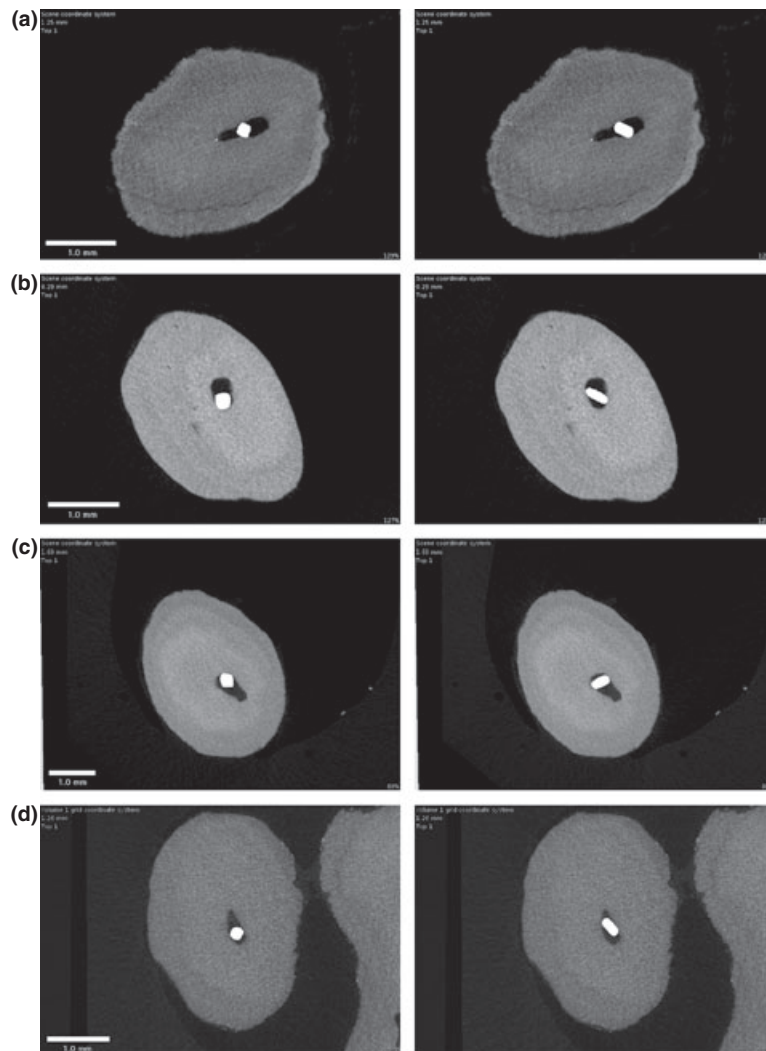
IAF, initial apical file; IAL, Initial Apical Lightspeed-instrument.

apical root canal dimensions using K-files was shown to be inaccurate, because the root canal shapes were predominantly oval in the palatal canal, mostly long oval or flattened in distobuccal canals and long oval in first mesiobuccal and second mesiobuccal canals.

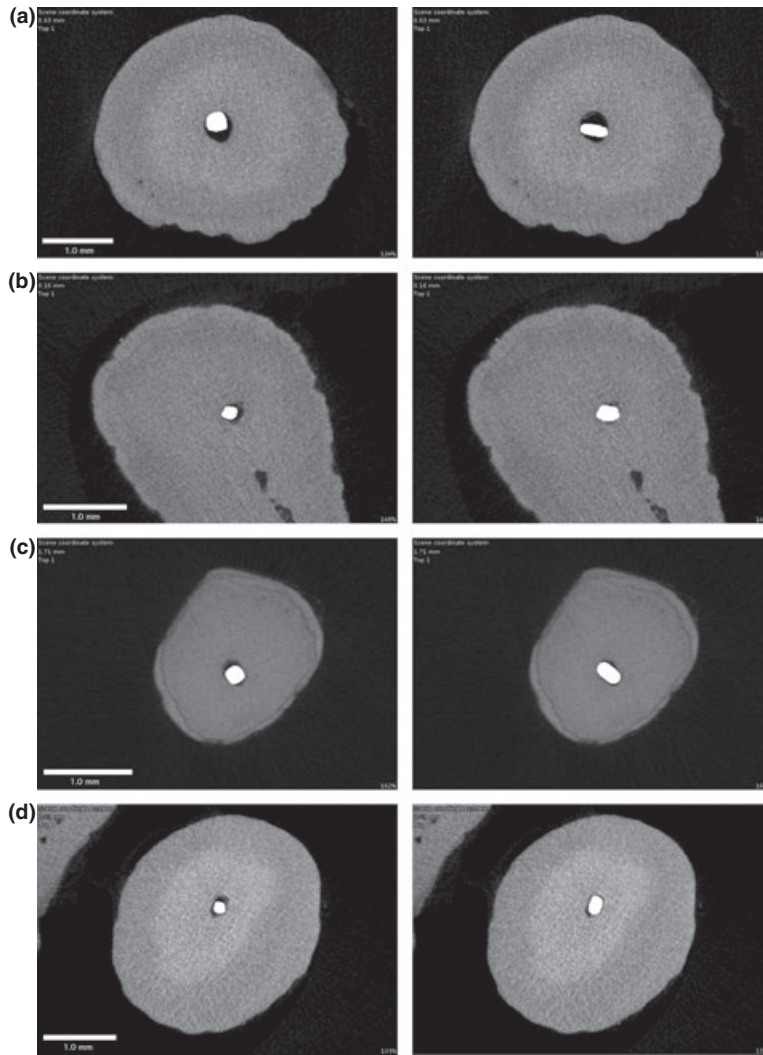
The hypothesis that the determination of the apical root canal diameter is more accurate when an instrument with an oval-shaped cross-section is used was supported by this study. However, in approximately

half of the canals (39 of 80), the smallest available LSX instrument (size 20) could not be inserted passively to full working length. One reason may be that the median short canal diameter in the apical part was too small to passively insert the LSX instruments (Table 4).

Orientation of the oval-shaped tip of the LSX instrument in the long-oval or flattened root canal is not predictable. It is also very difficult to guide because the shaft of the instrument is flexible. Corresponding 2D figures of roots with the IAF and IAL *in situ* are depicted (Figs 1 and 2). The IAL actually touched the root canal at two points in the evaluated cross-sections, but there were still large gaps between the instrument and the canal wall. The largest diameter of the instrument is not always oriented lengthways in the canal but wedged cross-ways or diagonally (Fig. 1). Apparently,



**Figure 1** Typical canal shapes and instrument positions [left column initial apical file (IAF) in place, right column Initial Apical Lightspeed-instrument (IAL) in place] in cases where LSX instruments were not oriented lengthways in the root canal. In these cases, the LSX instruments were not able to approximately predict the large root canal diameter (Panel a, distobuccal canal, IAF size 20, IAL size 25; Panel b, palatal canal, IAF size 25, IAL size 30; Panel c, palatal canal, IAF size 25, IAL size 30; Panel d, distobuccal canal, IAF size 20, IAL size 30).



**Figure 2** Typical canal shapes and instrument positions [left column initial apical file (IAF) in place, right column Initial Apical Lightspeed-instrument (IAL) in place] in cases where LSX instruments could accurately reflect the large apical canal diameter (Panel a, palatal canal, IAF size 30, IAL size 35; Panel b, first mesiobuccal canal, IAF size 15, IAL size 20; Panel c, palatal canal, IAF size 20, IAL size 25; Panel d, distobuccal canal, IAF size 15, IAL size 20).

**Table 4** Diameters in the apical part of root canals (1 mm short of WL) in canals where the smallest LSX instrument could be inserted to working length and in canals where LSX instruments could not be inserted to working length; all presented as medians and inter-quartile ranges

|                | Canals where LSX size 20 could be inserted | Canals where LSX size 20 could not be inserted |
|----------------|--|--|
| Long diameter  | 0.50 (0.24)                                | 0.43 (0.09)                                    |
| Short diameter | 0.29 (0.12)                                | 0.15 (0.07)                                    |

Differences between the two groups were statistically significant ( $P < 0.05$  and  $P < 0.0001$  for long and short diameter, respectively).

the tactile sense of the operator using the very flexible LSX instrument was insufficient. Twisting of NiTi prevents proper scouting and makes it more difficult

to guide the oval-shaped instrument tip into the right position through a curved canal. In some cases, the canal anatomy can be more narrow coronally from the working length (Dummer *et al.* 1984, Weiger *et al.* 2006).

Where determination with both instrument types was possible, the IAL size was one to three sizes larger than that of the IAF in almost all canals, and the large diameter of the apical portions of the root canals was better reflected by the oval-shaped LSX instrument than by the K-file (Figs 1 and 2). The median ratio of the IAL size to the long canal diameter was greater than that of IAF (78.1% and 46.3%, respectively, Table 3).

Weiger *et al.* (2006) evaluated a clinical method to determine the optimal apical preparation size using

special nontapered instruments. To achieve complete cutting of the inner layers of the dentine walls in 70–90% of the cases, an apical enlargement by 6–8 file sizes was required in the maxillary molar canals under investigation (Weiger et al. 2006). In the present study, the mean difference between long and short canal diameter was 0.21 mm in first mesiobuccal, 0.43 mm in second mesiobuccal, 0.28 mm in distobuccal and 0.24 mm in palatal canals (Table 4). These observations are in line with those of Weiger et al. (2006) and support the need to revise the long-held concept by Weine (1972), who advocated enlarging the apical part of the root canal to three sizes larger than the IAF.

Because  $\mu\text{Ct}$  could not be used clinically, measurement of the original canal anatomy is not possible and the practitioner has to rely on tactile sense. In this context, an apical sizing instrument with a flattened cross-section appears to be beneficial. Unfortunately, small instruments of this type are currently not available. For this reason, apical sizing in narrow canals should be performed during a later preparation step, i.e. performing the crown-down preparation to 1 or 2 mm short of working length.

Future experiments should aim at identifying ideal tools for apical sizing. In addition, more information is necessary regarding the importance of removing potentially infected dentine from the apical area and also on the impact of remaining dentine thickness after this procedure.

## Conclusions

Precise estimation of the apical canal dimensions was not possible. However, the large diameter of the root canal was better reflected by the oval-shaped LSX instrument tip than by the round, tapered K-file. In roughly half of the canals, the smallest available LSX instrument could not be inserted passively to full working length because the short canal diameter in the apical part was too small.

## Acknowledgements

We gratefully acknowledge the assistance of Dr Áine Lennon.

## References

Dummer PM, McGinn JH, Rees DG (1984) The position and topography of the apical canal constriction and apical foramen. *International Endodontic Journal* **17**, 192–8.

- Gani O, Visvisian C (1999) Apical canal diameter in the first upper molar at various ages. *Journal of Endodontics* **25**, 689–91.
- Hess W (1917) Zur Anatomie der Wurzelkanäle des menschlichen Gebisses mit Berücksichtigung der feineren Verzweigungen am Foramen apikale. *Schweizerische Vierteljahresschrift Zahnheilkunde* **27**, 1–52.
- Ibelli GS, Barroso JM, Capelli A, Spano JC, Pecora JD (2007) Influence of cervical preflaring on apical file size determination in maxillary lateral incisors. *Brazilian Dental Journal* **18**, 102–6.
- Iqbal MK, Banfield B, Lavorini A, Bachstein B (2007) A comparison of LightSpeed LS1 and LightSpeed LSX NiTi rotary instruments in apical transportation and length control in simulated root canals. *Journal of Endodontics* **33**, 268–71.
- Jou YT, Karabucak B, Levin J, Liu D (2004) Endodontic working width: current concepts and techniques. *Dental Clinics of North America* **48**, 323–35.
- Kerekes K, Tronstad L (1977a) Morphometric observations on root canals of human premolars. *Journal of Endodontics* **3**, 74–9.
- Kerekes K, Tronstad L (1977b) Morphometric observations on root canals of human anterior teeth. *Journal of Endodontics* **3**, 24–9.
- Kerekes K, Tronstad L (1977c) Morphometric observations on the root canals of human molars. *Journal of Endodontics* **3**, 114–8.
- Lang H, Korkmaz Y, Schneider K, Raab WH (2006) Impact of endodontic treatments on the rigidity of the root. *Journal of Dental Research* **85**, 364–8.
- Paqué F, Zehnder M, Marending M (2010) Apical fit of initial K-files in maxillary molars assessed by micro-computed tomography. *International Endodontic Journal* **43**, 328–35.
- Pecora JD, Capelli A, Guerisoli DM, Spano JC, Estrela C (2005) Influence of cervical preflaring on apical file size determination. *International Endodontic Journal* **38**, 430–5.
- Tan BT, Messer HH (2002) The quality of apical canal preparation using hand and rotary instruments with specific criteria for enlargement based on initial apical file size. *Journal of Endodontics* **28**, 658–64.
- Usman N, Baumgartner JC, Marshall JG (2004) Influence of instrument size on root canal debridement. *Journal of Endodontics* **30**, 110–2.
- Weiger R, John C, Geigle H, Löst C (1999) An in vitro comparison of two modern apex locators. *Journal of Endodontics* **25**, 765–8.
- Weiger R, Bartha T, Kalwitzki M, Löst C (2006) A clinical method to determine the optimal apical preparation size. Part I. *Oral Surgery, Oral Medicine, Oral Pathology, Oral Radiology and Endodontics* **102**, 686–91.
- Weine F (1972) *Endodontic therapy*. St. Louis: C.V. Mosby, 209–22.
- Wu MK, Wesselink PR (1995) Efficacy of three techniques in cleaning the apical portion of curved root canals. *Oral Surgery, Oral Medicine, Oral Pathology, Oral Radiology and Endodontics* **79**, 492–6.

Wu MK, Roris A, Barkis D, Wesselink PR (2000) Prevalence and extent of long oval canals in the apical third. *Oral Surgery, Oral Medicine, Oral Pathology, Oral Radiology and Endodontics* **89**, 739–43.

Wu MK, Barkis D, Roris A, Wesselink PR (2002) Does the first file to bind correspond to the diameter of the canal in the apical region? *International Endodontic Journal* **35**, 264–7.